

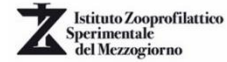
71°



**SOCIETÀ ITALIANA DELLE
SCIENZE VETERINARIE**

CONVEGNO SISVET

In collaborazione con



XVII Convegno SICV

XV Convegno SIRA

XIV Convegno AIPVET

XII Convegno SOFIVET

IV Convegno RNIV

I Convegno ANIV

28 Giugno - 1 Luglio 2017

Università degli Studi di Napoli "Federico II"

Corso Umberto I, 40 - 80138 - Napoli

I contributi presenti negli Atti del 71° Convegno Sisvet 2017

potranno essere citati utilizzando il codice ISBN 9788890909245

AIPVET

Oncology I

CEREBRAL INTRAVASCULAR LYMPHOMA IN DOGS

S. Degl'Innocenti (1), N. Della Camera (2), C. Falzone (2) and C. Cantile (1)

(1) Università di Pisa, Dipartimento di Scienze Veterinarie; (2) Medico veterinario libero professionista.

Intravascular lymphoma (IVL) is a rare angiotropic large-cell lymphoma in which neoplastic lymphocytes proliferate within the lumina of small blood vessels in the absence of a primary extravascular mass or leukemia. IVL is described in humans, dogs, one cat and one horse. The clinical symptoms of the disease are dependent on the specific organ involvement, which most often includes the central nervous system (CNS) and skin. The aim of our study was to characterize the clinical and neuropathological features of 10 cases of canine IVL restricted to the CNS. The study included 6 females and 4 males with an average age of 8 years (range 2.5 to 13 years). Immunohistochemistry (IHC) using anti-CD3 and anti-CD20 antibodies was performed to typify the neoplastic lymphocytes. Anti-CD44 and anti-CD29 antibodies were used to investigate the pathogenetic mechanism leading to the intravascular aggregation of the neoplastic lymphocytes, since CD44 and CD29 are molecules known to be involved in lymphocyte and endothelial adhesion phenomena. The same IHC panel was also applied on 8 cases of primary and metastatic canine CNS lymphoma in order to compare IVL immunoreactivity. The main clinical signs shown by dogs with cerebral IVL were depression, seizures and gait deficits. Magnetic resonance imaging showed several areas of hyperintensity distributed mainly in the forebrain with almost no significant enhancement post intravenous gadolinium administration. Grossly, lesions were found in 6 cases and included focal extensive or multiple hemorrhagic areas. Microscopic examination revealed numerous veins and capillaries filled with neoplastic lymphoid cells, involving both neuroparenchymal and meningeal vessels, and accompanied by various degrees of edema, hemorrhage and thrombosis. Three IVLs were typified as T-cell (CD3⁺), 3 as B-cell (CD20⁺) and 4 as non-B non-T (CD3⁻, CD20⁻). Regarding primary and metastatic canine CNS lymphomas, 4 were classified as T-cell, 3 as B-cell, and one as non-B non-T. In IVLs, neoplastic lymphocytes showed marked expression of CD44, whereas in primary and metastatic lymphomas CD44 positive cells were detected only in 2 cases. CD29 immunolabeled cells were observed in 4 IVLs and in one primary CNS lymphoma. In human IVL, CD44 is invariably expressed on the cytoplasmic membrane of neoplastic cells, presumably predisposing to the formation of lymphocytes aggregates. Moreover, the transvascular lymphocyte migration could be impaired because of lack of CD29 expression on neoplastic cells, limiting their proliferation within the intravascular compartment. CD44 immunoreactivity in canine IVL was consistent with the findings reported in human IVL, whereas CD29 was inconsistently immunonegative, confirming only partially the pathogenetic mechanism suggested for the human counterpart.

Jalkanen S et al: Lymphocyte homing receptors and adhesion molecules in intravascular malignant lymphomatosis. *Int J Cancer* 1989; 44: 777-782. McDonough SP et al: Clinicopathological and immunophenotypical features of canine intravascular lymphoma (malignant angioendotheliomatosis). *J Comp Pathol* 2002; 126: 277-288. Ponzoni M et al: Lack of CD29 (β1 Integrin) and CD54 (ICAM-1) adhesion molecules in intravascular lymphomatosis. *Human Pathol* 2000; 31: 220-226. Ponzoni M, Ferreri AJM: Intravascular lymphoma: a neoplasm of 'homeless' lymphocytes? *Hematol Oncol* 2006; 24: 105-112.

A COMPARATIVE ASSESSMENT OF HISTOLOGY, IMMUNOHISTOCHEMISTRY AND CLONALITY IN THE DIFFERENTIAL DIAGNOSIS OF SPLENIC LYMPHOID NODULES IN DOGS

*A. Rigillo (1), S. Sabattini (1), M. Giantin (2), M. Dacasto (2), C. Matteo (1), R.M. Lopparelli (2),
M. Mengoli (1), A. Renzi (1) and G. Bettini (1)*

(1) Alma Mater Studiorum – Università di Bologna, Dipartimento di Scienze Mediche Veterinarie;

(2) Università degli Studi di Padova, Dipartimento di Biomedicina Comparata e Alimentazione.

Canine splenic lymphoid nodules are histologically classified as indolent lymphomas (marginal zone lymphoma – MZL; mantle cell lymphoma - MCL) or lymphoid nodular hyperplasia, simple (SNH) or complex (CNH) type. Nevertheless, their differentiation may be difficult on a plain morphological basis, because of similar histologic appearance and poorly defined diagnostic criteria. In order to evaluate the possible contribution of image analysis, immunohistochemistry (IHC) and clonality, we reviewed 30 surgical samples of splenic lymphoid nodules histologically diagnosed as 10 MZL, 3 MCL, 11 SNH and 6 CNH. Proliferative activity was evaluated together with immunophenotype with a double staining technique for Ki67-index and CD3 or CD79a. Image analysis was then performed to assess in each nodule the percentage of T/B-cell areas and the corresponding proliferative activity. Three cases formerly diagnosed as MZL were reclassified as lymphoid hyperplasia upon evaluation of CD3 and CD79a patterns. The percentage of CD79a-positive areas was significantly higher in lymphomas (mean, $3.5 \pm 11.3\%$) compared with nodular hyperplasia (mean, $24.2 \pm 10.9\%$; $P = 0.001$). The proliferative activity of B-cells was lower in hyperplastic lesions than in lymphomas (median Ki67-index, 2.2% and 5.5%, respectively; $P=0.014$). Regardless of the histological diagnosis, Ki67-index was higher in non-B cells than in B cells in all cases (median, 18.7%; $P < 0.001$). The best cut off value discriminating between lesions diagnosed as hyperplasia or lymphoma was a B cell area of at least 27% with a Ki67 index above 3%. None of the dogs except one received adjuvant treatment besides splenectomy. Dogs were monitored for a median follow-up time of 947 days (range, 133-2261) and in no case a relapse was documented. Overall median survival time was 1237 days, with no significant difference between lymphomas and hyperplasia. Surprisingly, clonality results showed a monoclonal or biclonal rearrangement also in the vast majority of cases diagnosed as hyperplasia, suggesting a pathogenetic continuum with lymphoma. In conclusion, the combination of histology and IHC may help to improve the diagnostic accuracy of canine splenic lymphoid nodules, even if the long-term behavior of these lesions appears similar

[1] Moore A.S., Friemberger A.E., and Sullivan N.(2012) Histologic and immune-histochemical review of splenic fibrohistiocytic nodules in dogs. *J Vet Inter Med.*;26:1164-1168. [2] Valli V.E., Vernau W., and de Lorimier L.P. (2006) Canine indolent nodular lymphoma. *Vet Pathol.* 43 : 241-256. [3] Valli V.E., Kass P., San Myint M., and Scott F. (2013) Canine lymphoma: The effect of age, stage of disease, subtype of tumor, mitotic rate and treatment protocol on overall survival. *Vet Pathol.* 50:728-748.

EXPRESSION ANALYSIS OF MICRORNAS IN FFPE SAMPLES OF CANINE CUTANEOUS AND ORAL MELANOMA BY RT-QPCR

Lecchi C¹, Catozzi C¹, Gini C¹, Cecilian F¹, Finotello R², Ressel L³

(2) Università degli Studi di Milano, Dipartimento di Medicina Veterinaria (DIMEVET)

(3) Department of Small Animal Clinical Science, Institute of Veterinary Science University of Liverpool, UK

(4) Department of Veterinary Pathology and Public Health, Institute of Veterinary Science, University of Liverpool, UK.

MicroRNA (miRNA), a class of small, non-coding RNA - regulating post-transcriptionally protein expression - are emerging as clinical biomarkers in many pathologies, including cancer [1]. Since miRNA are supposed to represent fundamental key regulators, better understanding of melanoma tumour biology is essential to improve both disease grading and staging and, consequently, therapy options and prognosis. The aim of the study was to investigate whether miRNA expression can vary in canine melanoma samples derived from formalin-fixed-paraffin-embedded (FFPE) tissues. Experimental design of the study included three groups, each one composed of 7 animals: i) control healthy skin group ii) oral melanoma group iii) skin melanoma group. Two tissue slides were used for miRNA extraction. The expression levels of seven miRNA - miR-145, miR-146a, miR-425-5p, miR-223, miR-365, miR-155 and miR-134 - were detected and assessed by qPCR using TaqMan[®] probes [2-7]. Five miRNA were significantly up-(n=3) or down-(n=2) regulated. In details, miR-146a and miR-155 abundance was increased as compared with control in both oral and skin melanoma ($p = 0.004$ and 0.014 and $p = 0.043$ and 0.035 respectively), while the levels of miR-145 and miR-365 were lower ($p = 0.018$ and 0.008 and $p = 0.01$ and 0.028 , respectively). MiR-425-5p was upregulated ($p = 0.039$) only in skin melanoma. Furthermore, functional analysis, carried out using miRNet web-based tool [8], showed that 76 genes related to cancer-associated pathways were possible target of these five microRNA ($p = 6.95E-9$); in particular, 21 target genes were associated with melanoma ($p = 1.47E-5$), including BRAF, KRAS, AKT1 and CDK, E2F, FGF, EGFR and PIK3 families. In conclusion, miR-145, miR-146a, miR-425-5p, miR-365 and miR-155 are differentially expressed in melanoma and healthy FFPE samples, suggesting that they may play a role in canine melanoma pathogenesis and/or progression.

(1) Peng and Croce. The role of MicroRNAs in human cancer. *Signal Transduction and Targeted Therapy*. 2016; 1, 15004 (2) Varamo et al., MicroRNA role as potential biomarkers and key regulators in Melanoma. *Genes, chromosomes and cancer*. 2017; 56:3-10 (3) Liu et al., miR-425 inhibits melanoma metastasis through repression of PI3K-Akt pathway by targeting IGF-1. *Biomed Pharmacother*. 2015;75:51-7 (4) Wagner et al., Comparison of non-coding RNAs in human and canine cancer. *Frontiers in Genetics*. 2013; 4:46-2 (5) Sand et al., Comparative microarray analysis of microRNA expression profiles in primary cutaneous malignant melanoma, cutaneous malignant melanoma metastases, and benign melanocytic nevi. *Cell Tissue Res*. 2013;351(1):85-98 (6) Noguchi et al, Comparative study of anti-oncogenic MicroRNA-145 in canine and human malignant melanoma. *J. Vet. Med. Sci*. 2012; 74(1):1-8 (7) Segura et al., MicroRNA and cutaneous melanoma: from discovery to prognosis and therapy. *Carcinogenesis*. 2012; 33:1823-1832 (8) Fan et al., miRNet - dissecting miRNA-target interactions and functional associations through network-based visual analysis. *Nucleic Acids Research*. 2016; 44:135-141

PATTERNS OF MIRNA EXPRESSION IN CANINE MENINGIOMA

Greta Foiani (1), Gabriella Guelfi (1), Gabriel Falcinelli (1), Maria Teresa Mandara (1)

(1) Università degli Studi di Perugia, Dipartimento di Medicina Veterinaria.

miRNAs are a class of non-coding small RNAs highly conserved between human and dog [1]. They regulate gene expression by binding to complementary sequences in their target mRNAs, promoting their degradation or repressing their translation. Increasing evidences support that miRNAs play an important role in tumor development as oncogenes or tumor suppressors. In recent years miRNAs have become a major focus of research also in veterinary and comparative oncology.

The aim of this study is to investigate the biological role of miRNAs in the meningioma of the dog, trying to contribute to understanding the molecular bases of the most common primary cerebral tumor in this species. The expression of 12 miRNAs (miR-335, miR-200a, miR-98, miR-96, miR-190a, miR-29c, miR-219-5p, miR-155, miR-146a, miR-145, miR-136, miR-451) associated with human meningioma has been analyzed by qRT-PCR in 41 FFPE canine tumors and compared to normal arachnoid tissue [2, 3, 4]. The correlation between miRNA expression and tumor grade/histotype has been evaluated.

Total RNA was extracted with FFPE-RNA Purification Kit (Norgen). Reverse-transcription, pre-amplification, and PCR reactions were performed using TaqMan Advanced miRNA Assays (Applied Biosystems). One way ANOVA followed by Tukey's post-hoc test and t-test were used to compare miRNA expression among groups (Rcmdr, R Commander).

Our analyses revealed miR-29c and miR-200a upregulation in grade III meningiomas. Furthermore, miR-200a was upregulated in anaplastic meningiomas whereas miR-98 and miR-136 were downregulated in papillary and meningothelial meningiomas, respectively. Finally, miR-145 was downregulated in meningiomas compared to normal arachnoid tissue.

In contrast to our findings, in human meningioma the expression of miR-29c decreases with tumor grade, in association with high recurrence rate [3]. Similarly, miR-200a upregulation in canine grade III and anaplastic meningiomas is an unexpected result considered the proved tumor suppressor activity of this miRNA in human meningioma. In fact, miR-200a inhibits growth and migration of neoplastic meningeal cells increasing the expression of E-cadherin, blocking the Wnt/ β -catenin signaling pathway and targeting NMHCIIb [2]. As for histotypes, the different miRNA expression observed suggests a possible role of miR-200a, miR-98 and miR-136 in guiding histological pattern expression.

Our study represents the first attempt to investigate miRNAs potentially involved in the biological behavior of canine meningioma. Based on data reported for human meningioma, a different biological role of the examined miRNAs should be taken into consideration in the canine neoplasia.

[1] Wagner S. et al. Comparison of non-coding RNAs in human and canine cancer. *Frontiers in genetics*, 4:46, 2013. [2] Saydam O. et al. Downregulated microRNA-200a in meningiomas promotes tumor growth by reducing E-cadherin and activating the Wnt/beta-catenin signaling pathway. *Molecular and Cellular Biology*. 29:5923-40, 2009. [3] Zhi F. et al. A microRNA expression signature predicts meningioma recurrence. *International Journal of Cancer*. 132:128-36, 2013. [4] Kliese N. et al. miRNA-145 is downregulated in atypical and anaplastic meningiomas and negatively regulates motility and proliferation of meningioma cells. *Oncogene*. 32:4712-20, 2013.

THE DIAGNOSTIC ROLE OF IMMUNOHISTOCHEMISTRY IN FISH CANCER IDENTIFICATION

Giovanni Lanteri (1), Giuseppe Mazzullo (1), Roberto Puleio (2), Daniele Macrì (2), Chiara Brachelente (3), Gabriele Ghisleni (4), Fabio Marino (5)

(1) Università degli Studi di Messina, Dipartimento di Scienze Veterinarie, Italia. (2) IZS Sicilia, Italia. (3) Università degli Studi di Perugia, Dipartimento di Medicina Veterinaria, Italia. (4) Libero professionista, Italia.
(5) Università degli Studi di Messina, Dipartimento di Scienze Chimiche, Biologiche, Farmaceutiche ed Ambientali, Italia.

Tumors are nowadays more and more found in aquatic animals and the study of carcinogenesis is becoming very important in the field of research. Particularly in teleosts almost all tumour types affecting all tissues and organs have been reported. The diagnosis of tumors in fish is not always easy to achieve and the use of antibodies is today essential in order to make a definitive and unambiguous identification. In this order, different tumor types, such as skin papilloma, dermal fibroma, dermal schwannoma, skin melanoma, sampled from 7 fishes were studied and their gross, histological, histochemical and immunohistochemical patterns are reported. The following antibodies were used: pancytokeratins, vimentin, S-100, melan A, calretinin, GFAP, actin, and Ki-67. The data obtained underline the importance and the value of immunohistochemistry as diagnostic tool in fish tumor diagnosis and especially for the identification of the origin of the tumor cells. Moreover, the first reports of papilloma in a bream, of fibroma in a Mediterranean steenbras, of schwannoma in a crucian carp are here provided.

EXPRESSION OF CARNITINE PALMITOYLTRANSFERASE 1 A IN CANINE MAMMARY TUMOURS. PRELIMINARY INVESTIGATIONS

*Nunzio Cacciola (1), Manuela Martano (2), Maria Francesca Sgadari (2), Karen Power (2),
Brunella Restucci (2)*

(1) Istituto di Biologia Agroambientale e Forestale CNR, Napoli; (2) Università degli Studi di Napoli, Dipartimento di Medicina Veterinaria e Produzione animale, Napoli

Neoplastic cells gain a survival and growth advantage by adapting their metabolism to respond to environmental stress, a process known as metabolic transformation. The best known aspect of this process is the Warburg effect, whereby cancer cells up-regulate glycolysis under aerobic conditions. However, neoplastic cells can undergo metabolic transformation utilizing other nutrients such as fatty acids, drawn from the microenvironment, to produce ATP. Fatty acid oxidation (FAO) is regulated by carnitine-palmitoyl-transferase system which is responsible for transporting long-chain Acyl-CoA from cytoplasm into mitochondria for β oxidation. The first component of this system is carnitine palmitoyltransferase 1 A (CPT1A) which catalyzes the FAO rate limiting step. A FAO involvement has been demonstrated in different human tumors including breast cancer, and, pharmacological inhibition of CPT1A can reduce cancer cell survival (1). Spontaneously occurring canine mammary tumors are known as suitable model for human breast cancer. Thus, the aim of the present study was to investigate FAO in 5 samples of normal mammary gland tissue, in 5 benign and 10 malignant spontaneous canine mammary tumors evaluating CPT1A expression by immunohistochemistry and Western blot analysis. Neoplastic samples were classified according to WHO criteria and divided into grades I to III, (G1 to G3) applying Elston Ellis parameters. Immunoreactivity was scored by two independent observers under blinded condition, selecting 20 fields at 400X magnification and counting immunostained cells. Results were expressed as percentage. In normal mammary glands, 98.2% out of epithelial ductal cells showed strong expression of CPT1A characterized by cytoplasmic small granules. Myoepithelial cells were negative. In G1 and G2 tumors, the intensity of immunostaining was weaker than in normal mammary gland, and the number of immunostained cells was decreased (68.2% and 57% respectively.). However, in these tumors clusters of neoplastic cells showed strong immunostaining for CPT1A, characterized by cytoplasmic large and widespread granules. In grade III tumors, the intensity of immunostaining was very weak and the number of positive cells was further decreased (14.6%). Western blot analysis confirmed the cross-reactivity of the anti-human CPT1A antibodies in canine mammary gland. The mechanisms mediating metabolic transformation in cancer remain still quite undefined. Our results show for the first time, the expression of CPT1A in canine normal mammary gland, in benign and malignant tumors. The upregulation of this enzyme observed only in some clusters of neoplastic cells in G1 and G2 carcinomas, suggests that only few cells can adapt to this alternative metabolic pathway. We hypothesize that the loss of CPT1A immunostaining in G3 carcinomas, could be the consequence of mitochondrial damage which would render FAO impossible.

1. Pucci S., Zonetti M.J.: Carinitinepalmitoyl transferase-1A (CPT1A): a new tumor specific target in human breast cancer, *Oncotarget*, 7,19982-19996, 2016.

EXPRESSION OF CD79A AND IMMUNOGLOBULINS IN THE EPITHELIUM OF CANINE MAMMARY GLAND TUMORS

Claudia Rifici, Giuseppe Mazzullo, Gabriele Marino, Alessandra Sfacteria

Dpt. of Veterinary Sciences, University of Messina

Immunoglobulins (Ig) are traditionally considered as an exclusive product of B cell lineage and as molecules that play a crucial role in the regulation of the immune system mechanisms. Noteworthy, in the last decades, has been highlighted that many physiological and pathological “non B” cells, including epithelial cells and neurons may also express immunoglobulins (i.e. IgA, IgG and IgM). Igs, and their receptor CD79a, have been found in human cancerous cells and their role in cancerogenesis, as well as the therapeutic usefulness, has been raising interest [1,2]. On the basis of similarities among the epidemiology, biological behaviors, histopathological presentation and risk factors between the human and dog, our aim was to evaluate the epithelial expression of immunoglobulins in mammary gland tumors of the female dog. By the mean of immunohistochemistry, epithelial expression for CD79a and IgG, IgA ed IgM on 43 cases of mammary lesions (10 hyperplasia, 10 simple carcinoma, 5 solid carcinoma, 8 micropapillary carcinoma and 10 cases of mixed carcinoma) was evaluated. At the same time, an evaluation of number and distribution of CD79a+ immune cells was performed. In the mammary gland the number of CD79a+ immune cells decreased in hyperplastic area; in the malignant lesions, above all in peritumoral stroma, a high increase in the number of CD79a+ immune cells was observed. Rare cells were detectable in the intratumoral stroma. Moreover, the positivity for the antibody CD79a was also detectable in the basal cells of the solid tumors and in glandular cells of simple and micropapillary carcinomas. Both in preneoplastic and neoplastic lesions even with differences in intensity and cell localization, epithelial cells showed a positivity to IgA and IgG while the positivity for IgM was weak or absent. On the basis of our preliminary results and literature data, we suggest that such as immune cells and molecules could be directly involved in the progression or regression of mammary gland tumors as underlined by recent scientific evidences [3,4,5,6]. The canine mammary gland tumor, already recognized as a model in comparative oncology, represents once again an important support for the advancement of the veterinary oncology.

[1] Chen Z., Qiu X., Gu J. 2009. Immunoglobulin expression in non-lymphoid lineage and neoplastic cells. *Am J Pathol* 174,1139-1148. [2] Hu D., Zheng H., Liu H. 2008. Immunoglobulin expression and its biological significance in cancer cells. *Cell Mol Immunol.* 5, 319-324. [3] Welinder C., Baldetorp B., Blixt O. 2013. Primary breast cancer tumours contain high amounts of IgA1 immunoglobulin: an immunohistochemical analysis of a possible carrier of the tumour-associated Tn antigen. *PLoS One* 8: e61749. [4] Yang B, Ma C, Chen Z, Yi W, McNutt MA, Wang Y, Korteweg C, Gu J. 2013. Correlation of immunoglobulin G expression and histological subtype and stage in breast cancer. *PLoS One* 8: e58706. [5] Ma C, Wang Y, Zhang G, Chen Z, Qiu Y, Li J, Luo J, Huang B, Jiang C, Huang G, Wan X, Korteweg C, Gu J. 2013. Immunoglobulin G expression and its potential role in primary and metastatic breast cancers. *Curr Mol Med.* 13: 429-37. [6] Hu F., Zhang L., Zheng J. 2012. Spontaneous production of immunoglobulin M in human epithelial cancer cells. *PLoS One* 7:e51423.

AIPVET

Forensic pathology I

EVALUATION OF MUSCULAR PROTEINS DEGRADATION TO DEFINE POST MORTEM INTERVAL (PMI) IN DOGS

Giuseppe Piegari (1), Rosario Fico (2), Alessandro Costagliola (1), Davide De Biase (1), Francesco Prisco (1), Serenella Papparella (1), Orlando Paciello (1)

(1) Dipartimento di Medicina Veterinaria e produzioni animali, Università degli Studi di Napoli, (2) Centro di Referenza Nazionale per la Medicina Veterinaria Forense, IZS Lazio e Toscana.

The delimitation of the postmortem interval (PMI) is a very important aspect in Veterinary Forensic Pathology (1). The time of death and survival period may be used to determine criminal charges in animal cruelty cases (1). Many post-mortem modifications have been studied in human, less in animals, but, to our knowledge, no one considered the modifications of muscles in dogs. The skeletal muscle could be a viable target tissue for PMI analysis because it has a much greater delay in postmortem change compared to other organs (4). The aim of the present study was to evaluate the immunoreactivity modifications of two cytoskeletal proteins, desmin and dystrophin in muscles of dead dogs over the time to establish if there were statistical correlation with increasing of the PMI. For this study, muscles of twenty-five adult dogs (age range 6-12 years) were evaluated for 6 days after death in standard condition of temperature (23°C). Muscle samples were obtained from the Vastus lateralis and Triceps brachii at different time of death (respectively 0, 3, 24, 48, 72, 96, 120 and 148 hours after death). All samples were immediately frozen in isopentane pre-cooled in liquid nitrogen, and stored at -80°C until further processed. Tissue sections of 10 µm were cut in a transverse plane with a cryostat and processed for immunohistochemistry and haematoxylin and eosin staining. Immunohistochemical analysis was performed using anti-desmin and anti-dystrophin antibody diluted 1:200 for 2 hours. The degree of the immunoreactivity was scored as follows: 4 (>80% positively stained fibers in the section); 3 (50-80% positively stained fibres in the section); 2 (30-50% positively stained fibres in the section); 1 (1-30% positively stained fibres in the section) and 0 (negative staining observed in the fibers of the section). The one way analysis of variance was used to compare degree of immunoreactivity among the different times of death. The histological examination showed foci of muscle disintegration characterized by ruptured fibres and a loss of cell borders after 4 days post mortem (dpm). Immunohistochemical examination showed a more rapid dystrophin degradation with complete disappearance of the immunoreactivity after 4 dpm. In contrast, desmin was detected in dog muscle for all 6 days of observation with progressive reduction of immunoreactivity cells during the time (P<0.001). This study demonstrates that the muscle proteins have a time dependent degradation. Moreover, our immunohistochemical findings indicate that there is a difference in degradation among the various proteins of the muscle during storage. These results were in line with previous studies performed in fish muscle and suggest a different resistance of this protein to the process of autolysis (2,3). These studies will be useful to better evaluate the PMI in Forensic Veterinary Pathology.

[1] Brooks J.W. Postmortem Changes in Animal Carcasses and Estimation of the Postmortem Interval, *Veterinary Pathology*, 53:929-40, 2016 [2] Gaballero et al. Post mortem changes produced in the muscle of sea bream (*Sparus aurata*) during ice storage, *Acquaculture*, 291:210-216, 2009 [3] Cheryl et al. The effect of post-mortem delay on immunohistochemical labelling—a short review, *Comparative Clinical Pathology*, 20:95-101, 2011 (4) Vass et al. Decomposition chemistry of human remains: a new methodology for determining the postmortem interval. *Journal of Forensic Science*, 47:542–553, 2002.

ANIMAL ABUSE AND INTERPERSONAL VIOLENCE: THE ROLE OF THE VETERINARIAN IN FORENSIC MEDICINE

Attilio Corradi, Cristina Marchetti

Università degli Studi di Parma, Dipartimento di Scienze Medico-Veterinarie.

In recent years, investigations on animal abuse and interpersonal violence have demonstrated a strong relationship between these two forms of aggressive behaviours. Animal welfare, professionals, and social services now acknowledge that episodes of cruelty to animals, as well as maltreatment, domestic violence, and abuse of the elderly, are closely related. This phenomenon is commonly referred to as "THE LINK".

It is imperative that changes in social policies are introduced in order to raise awareness about this subject, and also that professional figures, who are involved in various ways in the fight against violence, develop collaborative approaches to limit animal abuse and other forms of domestic violence. We know that no professionalism, alone, can successfully deal with this alarming situation. Breaking the cycle of violence has become a top priority for today's society.

Understanding and tackling the connection between animal violence and violence inflicted on people represents an important tool for veterinary surgeons to protect animals' welfare.

The current problem related to the relationship between acts of cruelty to animals and violence against human beings is largely represented by the role of veterinarian in the recognition of abuse on domestic and wild animals and the ability to produce clinical and pathological evidence.

It is therefore necessary to undertake a university education programme to recognise and document external/internal body injuries suggesting abuse.

Veterinarians have many opportunities in civil and professional life to play their part in preventing crimes in the "One Health" perspective.

In the US as well as in some European countries (The Netherlands, the UK, Spain and Sweden) (National Link Coalition - June 28, 2016 - Minneapolis), strategies for the detection of animal abuse have been adopted in order to prevent violence towards the weaker categories.

This study aims to raise academic awareness about cruelty to animals, to encourage veterinarians to include non-accidental injuries (NAIs) in differential diagnosis and to report animal abuse cases, guaranteeing, at the same time, their anonymity. We will also present a selection of case studies.

American Veterinary Medical Association. Resolution #1 2012 Regular Winter Session: Policy on Animal Abuse and Animal Neglect. Arkow P. 2015 Recognizing and responding to cases of suspected animal cruelty, abuse, and neglect: what the veterinarian needs to know. *Veterinary Medicine: Research and Reports*. 6 349–359. BVA Congress Animal and human abuse: an uncomfortable link 2014 *Veterinary Record* 175: 579-580. Canadian Veterinary Medical Association Animal Abuse Position Statement. <http://www.canadianveterinarians.net/documents/animal-abuse>. Accessed July 29, 2015. Factors in the Assessment of Dangerousness of Perpetrators of Animal Cruelty. Randall Lockwood ASPCA. Lockwood R. Arkow P 2016 Animal Abuse and Interpersonal Violence: The Cruelty Connection and Its Implications for Veterinary Pathology. *Veterinary Pathology* Vol. 53(5) 910-918 . National Link Coalition. More Canadian vets now required to report suspected cruelty. *LINK-Letter*. 2015;8(8):1. Royal College of Veterinary Surgeons. Guide to Professional Conduct for Veterinary Surgeons: Animal Abuse, Child Abuse, Domestic Violence. London: The College 2003. Veterinary Council of New Zealand. Code of Professional Conduct: Animal Welfare. Wellington: The Council 2012.

BIOMARKERS OF PATHOLOGICAL CHANGES IN VETERINARY FORENSIC SCIENCE. A CASE STUDY ON FATAL HYPOTHERMIA IN A DOG

Pietro Badagliacca, Tiziana Di Febo, Antonio Cocco, Ludovica Di Renzo, Gabriella Di Francesco, Daniela Morelli, Manuela Tittarelli

Istituto Zooprofilattico Sperimentale dell'Abruzzo e del Molise "G. Capolare", Teramo.

Primary hypothermia occurs from prolonged exposure to cold, due to the failure of thermoregulation biochemical mechanism. The postmortem diagnosis of primary hypothermia as cause of death is often difficult in forensic sciences because of negative or inconstant macroscopic and microscopic findings [1]. In human legal medicine there have recently been promising results focused on the investigation of hypothermia-induced biomarkers. Particularly, the beta-hydroxybutyric acid (B-HB) as metabolite derived from fat catabolism via Acetyl-CoA pathway occurring in stress reactions following the insulin depletion, has been reputed a valid, measurable *intra vitam* indicator of fatal hypothermia [2].

We have retrospectively revised a post mortem diagnosis concerning a 4 year old Pincher, female, housed outdoor in a little enclosure, died during a night with external temperature under zero degrees. The macroscopic and histopathological findings as well as the screening for parasitological and microbiological infectious agents were inconclusive. Thereafter, the post-mortem diagnosis was newly reconsidered through a biochemistry approach.

The thawed liver and humor vitreous of animal were sampled and inocula from the liver homogenate and supernatant of centrifuged humor vitreous were analysed for the B-HB using a commercial enzyme-colorimetric probe (Beta-HB assay kit, ABCAM, UK). In the same test, two inocula from liver homogenates and one from vitreous of fresh carcasses of suddenly died dogs, previously tested negative for the presence of urinary ketones, were also analysed as in house negative controls.

The analyte concentrations in liver and vitreous of the test-animal were 38.47 and 11.18 ng/microl respectively and their percent variations face to negative controls were 32.5% (average of two livers) and 136.8% (humor vitreous).

Data from this few trial do not allow a conclusive speculation. However, the B-HB concentration in the vitreous, although of lesser level, would seem more discriminating. Further investigations are needed using, in absence of blood sample, instantly preserved inocula from cadaveric liver and fluids such as the humor vitreous, pericardial and cerebrospinal liquids.

The ketogenesis in dog is slower than in the man [3], thus the B-HB concentration reaches a significant level in a longer time. Hence, the proposed biochemistry approach could find a better application in the forensic cases when they make us suspect that *intra vitam* pathological changes affect the onset of the ketogenesis pathway such as in the prolonged exposure to cold injury or the prolonged fasting.

[1] Wohlsein et al. Thermal injuries in veterinary forensic pathology, *Vet Pathol*, 53:1001-1017, 2016. [2] Palmiere et al. Postmortem diagnosis of hypothermia, *In J Legal Med*, 128:607-614, 2014. [3] Crandall L.A. A comparison of ketosis in man and dog, *J Biol Chem*, 138:123-128, 1941

AIPVET

Oncology II

DISCOVERY OF *Ovis aries* PAPILOMAVIRUS 3-RELATED PROTEINS IN OVINE CUTANEOUS SQUAMOUS CELL CARCINOMA

Veronica Vitiello (1), Giovanni Pietro Burrai (1), Salvatore Pisanu (2), Carla Cacciotto (2), Daniela Pagnozzi (2), Maria Filippa Addis (2*), Tiziana Cubeddu (1), Salvatore Pirino (1)

(1) Department of Veterinary Medicine, University of Sassari, Italy. (2) Porto Conte Ricerche, Tramariglio, Alghero, Italy. (*) Current affiliation: Department of Veterinary Medicine, University of Milan, Italy.

Cutaneous squamous cell carcinoma (SCC) is widely described in animals and is the most common form of skin cancer in sheep [1]. The cause of this neoplasm appears to be multifactorial, although prolonged exposure to ultraviolet radiation and poor skin pigmentation are considered primary risk factors for tumor development [2]. However, oncogenic viruses, such as papillomaviruses (PVs) are often associated with benign and malignant tumors of the skin and mucous membranes in both humans and animals [3]. Recently, *Ovis aries* papillomavirus 3 (OaPV3) has been reported in ovine SCCs suggesting a role in the etiology of this neoplasm [4]. Nevertheless, the molecular pathways involved in viral-host interaction and skin cancer development has not been investigated. The aim of this study was to discover and validate differentially expressed proteins as candidate biomarkers of the OaPV3 infection in ovine cutaneous SCC, by proteomic and immunohistochemical (IHC) analysis. Fresh frozen non-SCC samples (N=3), OaPV3 negative SCCs (N=3) and OaPV3 positive SCCs (N=3) obtained from the udders of Sardinian ewes, were subjected to protein extraction and trypsin digestion with the Filter-Aided Sample Preparation procedure. Peptide mixtures were separated by liquid chromatography-mass spectrometry/mass spectrometry (LC-MS/MS) analysis and proteins identified by the Proteome Discoverer Software. Spectral counts and normalized spectral abundance factor were calculated in order to estimate the protein fold changes between the different histological samples and their relative abundance. IHC expression of deregulated proteins was analyzed in 10% formalin fixed and paraffin embedded non-SCC samples (N=10), OaPV3 negative SCCs (N=10) and OaPV3 positive SCCs (N=10). A list of 70 proteins, mainly involved in epithelial cell differentiation, extracellular matrix organization and apoptotic signaling pathway were differentially expressed in OaPV3 positive SCCs compared to non-SCC and OaPV3 negative SCCs samples ($P < 0.05$). Among the deregulated proteins, IHC results revealed an increased expression of cytokeratin 13 in the intermediate and superficial layers of keratin pearls in 10/10 OaPV3 positive SCCs, suggesting a putative role of this protein as OaPV3 biomarker in SCC. To the best of our knowledge this is the first proteomic approach investigating the deregulated biological processes related to the PV viral infection in ovine SCC, and it opens new insights on the pathogenesis of the virus-host interaction.

[1] Alberti et al. *Ovis aries* Papillomavirus 3: A prototype of a novel genus in the family Papillomaviridae associated with ovine squamous cell carcinoma, *Virology*, 407:352-359, 2010. [2] Ahmed AF, Hassanein KMA. Ovine and caprine cutaneous and ocular neoplasms, *Small Ruminant Research*, 106:189-200, 2012. [3] Munday JS, Kiupel M. Papillomavirus-associated cutaneous neoplasia in mammals, *Veterinary Pathology*, 47:254-264, 2010. [4] Vitiello et al. *Ovis aries* papillomavirus 3 in ovine cutaneous squamous cell carcinoma, *Veterinary Pathology*, In Press, DOI: 10.1177/0300985817705171, 2017.

EQUINE SARCOID: ROLE OF ANGIOGENESIS IN EXTRACELLULAR MATRIX (ECM) REMODELING

Karen Power, Manuela Martano, Ilaria Pagano, Paola Maiolino

Università degli Studi di Napoli, Dipartimento di Medicina Veterinaria e Produzioni Animali, Napoli

Equine sarcoids are benign fibroblastic skin tumors, locally invasive and rarely regressive [1]. They are notoriously difficult to treat, as they are associated with a high recurrence rate following surgical intervention [2]. It is accepted that they can develop subsequently to injury and scarring in genetically predisposed equines and that BPV-1 and less commonly BPV-2 are widely recognized as the causative agents of the disease [3]. Even though, the viral etiology, biology, morphology and epidemiology of equine sarcoids are known, the pathogenic events leading to the development of tumor are poorly understood. The aim of this study was to further understand the pathogenesis of sarcoids, investigating the immunohistochemical expression of Ki67, Bcl2, Factor VIII and VEGF in 15 sarcoid samples positive to BPV-1 and BPV-2, and 3 normal skin samples, previously processed by routine histological methods. Twenty fields of each section (at least 1,000 cells), at X400 magnification, were randomly chosen in order to quantify the immunohistochemical labeling and the results were expressed as percentage. In 100% of sarcoids samples, Ki67 immunoreactivity was strong in the majority of epidermal basal cells (> 90%) and weak to strong in dermal cells, in which the percentage ranged from 5% to 10%. Bcl2 immunoreactivity was detected in 8 of 15 sarcoids (53%). The percentage of Bcl2 positive fibroblasts, located immediately under the epidermis, ranged from 20 to 50% and the immunostaining was moderate. These results seem to suggest a central role of keratinocytes in the regulation of fibroblast proliferation and survival. Furthermore, in all sarcoids samples, VEGF showed a strong and finely granular cytoplasmic staining pattern in the majority (>90%) of keratinocytes, fibroblasts and endothelial cells. Numerous small vessels, often irregular in shape and without a distinct lumen, were immunostained with Factor VIII. These data seem to support the important role of VEGF in microvascular regeneration and that the partial or total occlusion of vascular lumina could be responsible to maintain a deficient oxygen gradient within the tissue and, paradoxically, exacerbate angiogenesis [4]. In conclusion, mild hypoxia could increase production of VEGF, which in turn could increase collagen production by fibroblasts and promoting their survival with concomitant intensification of ECM deposition and reduction of its degradation, due to an altered expression of MMPs and TIMPs [5]. These results strongly support the hypothesis that sarcoid formation is due to an imbalance between production and degradation of collagen and demonstrate that VEGF and hypoxia play a crucial role in its pathogenesis.

[1]Borzacchiello G. et al. Equine sarcoid: state of the art. *Ippologia*, 20:7–14, 2009.[2]Knottenbelt DC. A suggested clinical classification of the equine sarcoid. *Clin Tech in Eq Pract*, 4:278–95, 2005 [3]Chambers et al. Sequence variants of bovine papillomavirus E5 detected in equine sarcoids. *Virus Res*, 96 :141–5, 2003. [4]Deschene K. et al. Hypoxia regulates the expression of extracellular matrix associated proteins in equine dermal fibroblasts via HIF1. *J Dermatol Sc.* ;65(1):12-8., 2012. [5]Martano M. et al. Extracellular matrix remodeling in equine sarcoid: an immunohistochemical and molecular study. *BMC Vet Res*, 12:24, 2016.

***Felis catus* PAPILOMAVIRUS TYPE-2 E6 ONCOGENE IMPAIRS P53 PROTEIN STABILITY IN AN IN VITRO FELINE MODEL OF VIRAL PATHOGENESIS**

Gennaro Altamurai (1), Ghada Jebara (2), Giuseppe Borzacchiello (1)

(1) Università degli Studi di Napoli Federico II, Dipartimento di Medicina veterinaria e Produzioni animali (2) Unit of Immunology, Environmental Microbiology and Carcinogenesis (IMEC), Science Faculty of Bizerte, 7021 Zarzouna, University of Carthage, Tunisia

Felis catus PV type-2 (FcaPV-2) is the causative agent of feline squamous cell carcinomas (SCCs); its oncogenes E6 and E7 are transcribed in tumour samples and display transforming properties in vitro [1]. The p53 tumour suppressor protein is the main target of PVs E6 [2]. High risk human PVs (HR-HPVs) E6 promote ubiquitination of p53 by forming a ternary complex with the ubiquitin ligase E6AP, thus leading p53 to accelerated proteasomal degradation [2]. We have recently demonstrated that FcaPV-2 E6 binds to and impairs p53 protein level in feline epithelial cells [1]. The aim of this study was to gain new insights into the molecular events underlying p53 downregulation by FcaPV-2 E6 and check for E6AP expression in order to hypothesize its possible involvement as in human counterpart. CRFK cells stably expressing cloned FcaPV-2 E6 or the empty pCEFL vector were analysed by western blotting (WB) and double immunofluorescence (IF) for p53 and E6AP. To investigate p53 half-life, cells were treated with protein synthesis inhibitor cycloheximide 20 µg/mL for 0, 0.5, 1, 2.5, 5 hours (h) and subjected to WB for p53. Concomitantly, p53 and E6AP protein rescue was evaluated by WB after incubation of cells with the proteasome inhibitor MG132 30 µM for 4 h. Three feline oral SCCs cell lines (SCCF1, SCCF2, SCCF3), provided by Prof. T.J. Rosol from Ohio State University, were further included in the study as in vitro model of SCC. SCCF1, SCCF2 and SCCF3 cells were checked for p53 and E6AP expression by WB. All the WB experiments were normalized for β -actin as loading control. Expression of p53 was confirmed to be lower in CRFKE6 compared to CRFKpCEFL. Interestingly, E6AP protein levels showed the same trend. By IF staining E6AP co-localized with p53 in the cytoplasm of CRFKE6 but not in control cells. The p53 half-life was shorter in CRFKE6 and, importantly, the percentage of protein reduction with respect to time 0 was higher at each time point compared to control cells. Consistently, proteasome inhibition induced higher accumulation of p53 in cells expressing E6 and the same was observed for E6AP. Taken together, these results suggest that FcaPV-2 E6 may promote E6AP-p53 physical interaction and downregulate p53 protein by accelerating its degradation through the proteasome pathway, similarly to HR-HPVs E6 [2]. Moreover, the data indicate that FcaPV-2 E6 may promote E6AP proteasomal degradation as well, thus disrupting ubiquitination pathway and protein homeostasis within cells as already known for HPV16 [3]. In addition, consistent preliminary data were obtained in SCCF cells. Interestingly, p53 was undetectable and E6AP expressed at lower levels in SCCF3 cells, in which expression of FcaPV-2 E6 had been exclusively detected, suggesting a similar scenario in both the experimental cell models.

[1] Altamura G. et al. Transforming properties of *Felis catus* papillomavirus type 2 E6 and E7 putative oncogenes in vitro and their transcriptional activity in feline squamous cell carcinoma in vivo, *Virology*, 496:1-8, 2016. [2] Tommasino M. The human papillomavirus family and its role in carcinogenesis, *Seminars in Cancer Biology*, 26:13-21, 2014. [3] Kao W.H. et al. Human papillomavirus type 16 E6 induces self-ubiquitination of the E6AP ubiquitin-protein ligase, *Journal of Virology*, 74:6408-17, 2000.

PLACENTAL PAPILOMATOSIS IN WATER BUFFALO ASSOCIATED WITH BOVINE DELTAPAPILLOMAVIRUS

Valeria Russo (1), Orlando Paciello (1), Gaspare Zicarelli (2), Chiara Urraro (1), Dora Maria Ceccarelli (1), Francesca De Falco (1), Franco Roperto (3), Sante Roperto (1)

(1) Università degli Studi di Napoli Federico II, Dipartimento di Medicina Veterinaria e produzioni animali, Italia. (2) Medico veterinario, libero professionista, Caserta, Italia. (3) Università degli Studi di Napoli Federico II, Dipartimento di Biologia, Italia.

Bovine papillomaviruses (BPVs) are small DNA oncogenic viruses that can infect both epithelial and mesenchymal tissues of many animals causing both benign and malignant lesions. BPV comprise twenty-one types, which have been classified in to four genera: Deltapapillomavirus (BPV-1, -2, -13, 14), Xipapillomavirus (BPV-3, -4, -6, -9, -11, -12, -17 and -20), Epsilonpapillomavirus (BPV-5, -8). Dyoxipapillomavirus (BPV-7, -16 and -18). BPV-19 and BPV-21 are currently unclassified. The only papillomaviruses showing clear evidence of transmission across species barriers are Deltapapillomavirus. There are numerous reports of BPV infection in other animals including horses, cape mountain zebras, giraffe and antelope. In water buffalo, Deltapapillomavirus infection has been described in urinary bladder tumours [1], and in fibropapilloma of the skin and vulva [2]. To our knowledge, study of BPV infection associated with neoplastic lesions in placenta and other reproductive disorders have been poorly investigated in large animals. Recently BPV-2 infection has been shown to occur in placental trophoblast cells of pregnant cows [3]. In this study we describe the presence of Deltapapillomavirus in papillomas of the placenta in water buffalo (*bubalus bubalis*). Six buffalo placentas with evidence of papillomas were macroscopically examined. Samples from the lesions were collected for routine histology, immunohistochemistry and for subsequent molecular procedures. Macroscopically, the lesions were distributed in groups and ranged from 1 to 20 mm in diameter. The larger tumours appeared pedunculate, brown-white in color, with finger like projections. The smaller tumours were sessile, flattened, yellow with a pitted surface. Histologically, the lesions consist in a marked proliferation of epithelial cells with large, mildly eosinophilic and vacuolated cytoplasm, and nuclei with dense chromatin. DNA Deltapapillomavirus was amplified in papilloma samples. Western blot analysis revealed a marked E5 protein expression in placenta papilloma. A cytoplasmic E5 immunoreactivity was clearly shown in 50% of neoplastic epithelial cells, valuated selecting 10 fields at 20x magnification for each section. This study shows an association between Deltapapillomavirus infection and papilloma of the placenta; furthermore, papillomavirus may be involved in buffalo reproductive disorders. It is worthwhile noting that the incidence of reproductive disorders in large animals, like in fertility and abortions, caused by infectious agents is continuously increasing thus leading to substantial economic losses. This is even more so as the major causes of miscarriage are only rarely identified. Further investigation is needed to better understand the role of BPVs in placental pathology that may result in adverse pregnancy outcomes.

[1] Roperto et al. Bovine papillomavirus type 2 infects the urinary bladder of water buffalo (*Bubalus bubalis*) and plays a crucial role in bubaline urothelial carcinogenesis. *J Gen Virol.* 94, 403-408, 2013. [2] Silvestre et al. Bovine Papillomavirus Type 1 DNA and E5 Oncoprotein Expression in Water Buffalo Fibropapillomas. *Vet Pathol* 46, 636-641, 2009. [3] Roperto et al. Productive infection of bovine papillomavirus type 2 in the placenta of pregnant cows affected with urinary bladder tumors. *PLoS One* 7 (3), 2012.

AIPVET

Infectious Diseases

FATAL *Leucocytozoon* INFECTION IN A CAPTIVE GREY-HEADED PARROT (*Poicephalus robustus suahelicus* Reichenow, 1898)

Enrica Berio (1), Livio Galosi (2), Gian Enrico Magi (2), Susan C. Cork (3), Michael A. Peirce (4), Stefano Ferraro (5), Francesca Tiziana Cannizzo(1), Paola Pregel (1), Enrico Bollo (1), Frine Eleonora Scaglione (1), Giacomo Rossi (2)

(1) Department of Veterinary Science, University of Torino, Italy. (2) School of Biosciences and Veterinary Medicine, University of Camerino, Italy. (3) Ecosystem and Public Health Department, Faculty of Veterinary Medicine, University of Calgary, Canada. (4) Corresponding Associate, International Reference Centre for Avian Haematozoa, Queensland Museum, South Brisbane, Australia. (5) School of Science and Technology, Chemistry section, University of Camerino, Italy.

Haemoparasites infect all species of birds and are transmitted by arthropod vectors. Asymptomatic infections are common, but protozoal parasites can also cause the death of infected birds. A fatal infection by *Leucocytozoon* in a 1 year old captive female Grey-Headed Parrot (*Poicephalus robustus suahelicus*) is described. Necropsy was performed and tissues were collected for light and transmission electron microscopy, biomolecular examination and for evaluating iron accumulation in tissues. At necropsy severe spleen and liver enlargement were observed. Viscera appeared pale. Pulmonary oedema and some multifocal areas of necrosis in the liver and myocardium were also observed. Histologically, the presence of few schizonts were observed in hepatocytes and endothelial cells. A very large number of macrophages filled by characteristically shaped and basophilic merozoites suggestive of *Leucocytozoon* spp. was observed in the liver, spleen, and the lung parenchyma. Perls'stain showed that iron was present at a very high concentration in liver, both in macrophages and in hepatocytes. Spleen and kidney contained also scattered deposits of stainable iron. Ultrastructurally, numerous early or mature schizonts containing 1.5 to 3 µm in size, round to elongate merozoites were present within hepatocytes. All organs tested by nested-PCR resulted positive for *Leucocytozoon* spp. An iron level of 74.40 mg/kg was recorded in liver. *Leucocytozoon* frequently shows a higher pathogenicity compared to *Haemoproteus*, as the gametocyte phase can occur within either erythrocytes or leucocytes depending on the host and the species, frequently leading to megaloschizonts occurring in many organs and muscle tissues, and causing severe damage and necrosis. Fatal *Leucocytozoon* infections are rarely reported in parrots in Europe [1, 6] and haemoproteoza are rarely reported in African parrots. To the authors' knowledge there is only a single report of *Plasmodium* infection in *Poicephalus meyeri* [3]. Nevertheless, *Haemoproteus* has been recorded in *Poicephalus robustus* [4,5], in captive birds in London Zoo. The clinical history and post mortem examination of the individual bird suggest that death caused by *Leucocytozoon* in this aviary may be due to a range of predisposing factors influencing susceptibility to infection. Blood parasite infections and concurrent diseases can be associated with breakdown of tissues and blood cells resulting in excess iron accumulation in the liver and spleen [2]. Anamnesis associated with gross, histological, transmission electron microscopy, molecular and chemical findings, clearly indicates a fatal haemoproteoza infection in a captive Grey-Headed parrot. This case is the first description of fatal *Leucocytozoon* infection in an African Parrot and the first report of *Leucocytozoon* in psittacine birds in which morphological identification is confirmed by PCR analysis.

[1] Borst, G.H.A. 1973. Holland. Progr. Protozoology. 4, p. 55. [2] Cork, S.C. 2000. Avian Pathol. 29, pp. 7-12. [3] Lutz, H.L., Hochachka, W.M., Engel, J.I., Bell, J.A., Tkach, V.V., Bates, J.M., Hackett, S.J., Weckstein, J.D. PLoS One. 2015 May 18;10(5):e0128851. [4] Plimmer, H.G. 1912. Proc. Zool. Soc. Lond. pp. 406-419. [5] Plimmer, H.G. 1916. Proc. Zool. Soc. Lond. pp. 77-86. [6] Simpson, V.R. 1991. Vet. Rec. 13, pp. 30-32.

PATHOLOGICAL AND MICROBIOLOGICAL INVESTIGATIONS ON GREAT CORMORANT (*Phalacrocorax carbo*) POPULATIONS IN THE PROVINCE OF CUNEO (ITALY)

Scaglione Frine Eleonora (1), Pregel Paola (1), Mandola Maria Lucia (2), Rizzo Francesca (2), Squadrone Stefania (2), Zanet Stefania (1), Grosjacques Federica (1), Abete Maria Cesarina (2), Tizzani Paolo (1), Biolatti Bartolomeo (1), Cannizzo Francesca Tiziana (1), Bollo Enrico (1)

(1) Department of Veterinary Science, University of Torino, Torino, Italy. (2) Istituto Zooprofilattico Sperimentale del Piemonte, Lombardia e Valle d'Aosta.

The Great Cormorant is a cosmopolitan and ichthyophagous aquatic bird belonging to the *Suliformes* order [1]. It is a migratory species, although it has recently become nesting in some regions (e.g. Piedmont). Due to its demographic increase and to the damage caused to fish farms and rivers, this species is subjected to population control programmes.

Aims of the work were to evaluate the presence of diseases by anatomo-histopathological and microbiological investigations on cormorant, to hypothesise any public health risk and to evaluate environmental contaminants (cadmium and lead) to assess water pollution.

Fifty-seven animals were subjected to a necroscopic examination and sampled for microbiological, parasitological and toxicological investigations. Liver, lung, heart, spleen, kidney and skeletal muscle were fixed in 10% buffered formalin for histological examination. For virological (West Nile Virus, Newcastle Disease and Influenza A), bacteriological (*Borrelia burgdorferi*, *Chlamydia* spp., *Rickettsia* and *Coxiella burnetii*) and parasitological (*Toxoplasma gondii*, *Neospora caninum*, *Haemoproteus* spp., *Plasmodium* spp., *Leucocytozoon* spp. and gastrointestinal parasites) investigations, and for the quantification of cadmium and lead, samples were frozen at -20°C.

Histologically the most affected organ was the liver, with 54.7% animals showing lymphocytic infiltration. Virological and bacteriological examinations resulted negative, with the exception for *Chlamydia* spp. (6/57 animals were positive and in 5/6 cases *C. psittaci* was identified). Positivities for *Haemoproteus* spp., *Plasmodium* spp. and *Leucocytozoon* spp. were also detected. Helminths were found in 92.6%, 100% and 33.3% of animals examined for *Contracaecum rudolphii*, *Paryphostomum radiatum* and flatworms respectively. The quantification of heavy metals revealed normal values in liver and feathers for cadmium, whereas lead resulted increased in 6 subjects (1 liver and 5 feathers). Such deviations may indicate accumulation due to biomagnifications, or to direct environmental contact between the matrix and the pollutant [2].

[1] Grzimek B., 2003; Grzimek's Animal Life Encyclopedia. 2nd edition by Gale, Vol.08 Birds, 183-186, 201-205 pp. [2] Kim J., Koo T.H., 2008; Heavy metal concentrations in feathers of Korean shorebirds. Arch. Environ. Contam. Toxicol. 55: 122-128.

AIPVET

Miscellaneous

AN UNCOMMON CARDIOMYOPATHY IN A CAPTIVE CHIMPANZEE (*Pan troglodytes*)

Cristina Biolatti (1), Katia Varello (1), Alessandro Dondo (1), Alessia Di Blasio (1), Daniele Laguardia (2), Piero Laricchiuta (3), Claudio Caruso (1), Frine Eleonora Scaglione (4), Franco Guarda (4), Pier Luigi Acutis (1)

(1) Istituto Zooprofilattico Sperimentale del Piemonte, Liguria e Valle d'Aosta, Italia. (2) Zoo Safari Fasano, Italia. (3) Libero professionista, Italia. (4) Università degli Studi di Torino, Dipartimento di Scienze Veterinarie, Italia.

Heart disease is the main cause of death in captive chimpanzees (*Pan troglodytes*) reaching a prevalence of 68% in adult animals [1]. The present case report describes the findings of an uncommon cardiomyopathy in a captive chimpanzee.

A 41 year old male chimpanzee was submitted for post-mortem examination. The animal was hosted in a zoological garden. During late 2015, poor body conditions, depression, tachipnea and abdominal breathing were observed. A moderate pleural effusion was found, drained, and classified as transudate at cytology. Clinical and instrumental findings suggested the diagnosis of atrioventricular valve regurgitation and dilated cardiomyopathy. Even though a therapeutic protocol was promptly started, clinical conditions gradually deteriorated through the following months and eventually the animal was found dead.

A complete necropsy was performed. A subcutaneous abscess was observed on the left hemithorax, and a serous/hemorrhagic transudate was revealed at the opening of the thorax. The heart was markedly enlarged and lungs were compressed. The epicardium presented small fibrin depositions on the surface and the right ventricle was dilated. At the heart dissection, both atrioventricular valves were atrophic. Prominent nodular thickening of free margins of both valves was observed. Hepatomegaly and perihepatitis were also noticed.

Histologically, both atrioventricular valves were repleted with blood and foci of chronic mononuclear inflammation were observed. Myocardial fibres were extensively replaced with connective and adipose tissue and the remaining ones showed a marked variation in size. Interstitial fibrosis was diffusively detected and a considerable amount of oedema was evident between atrophied fibres. The lungs showed mild perivascular mononuclear cell infiltrates and alveolar oedema.

Several samples were submitted to bacteriological investigations. *Staphylococcus aureus* was isolated from lungs and exudate. Routine parasitological exam and molecular analyses (carried out for the detection of *Herpesviridae*, Hepatitis A, Hepatitis B, Hepatitis C, and *Toxoplasma gondii*) tested negative.

Fibrosing cardiomyopathy complicated by chronic endocarditis and toxic myocarditis was diagnosed.

Interstitial fibrosis is widely reported in aged chimpanzees and is considered a significant cause of cardiac disease in this species [1]. In the present case report, a secondary pathological chronic process has been found. The chronic trend and the growth of *S. aureus* in two specimens lead to presume that the cardiac lesions, other than interstitial fibrosis, could be caused by a slow dissemination of the bacterium and its toxins from the subcutaneous abscess. In humans *S. aureus* is considered the predominant cause of infective endocarditis [2]. Moreover *S. aureus* toxins have been shown to induce localized cytotoxicity and persistent inflammation, preventing the healing of the damaged site [3]. The findings described in this case report may help to understand cardiovascular disease in great apes.

[1] Seiler et al. Spontaneous Heart Disease in the Adult Chimpanzee (*Pan troglodytes*). J Med Primatol, 38: 51–58, 2009. [2] Federspiel et al. Endocarditis Trends in the United States Demonstrate Increasing Rates of *Staphylococcus aureus*: 1999–2008. Arch Intern Med. 172: 363–365, 2012 [3] Salgado-Pabón et al. Superantigens Are Critical for *Staphylococcus aureus* Infective Endocarditis, Sepsis, and Acute Kidney Injury. mBio, 4: e00494-13, 2013.

IMPRESSION CYTOLOGY OF HEALTHY OCULAR SURFACE IN HORSES: COMPARISON WITH CYTOBRUSH TECHNIQUE

F. Bonsembiante (1) A. Deganello (2), A. Perazzi (2). M.E. Gelain (1), I. Iacopetti (2)

(1) Department of Comparative Biomedicine and Food Science, (2) Department of Animal Medicine, Production and Health, of University of Padua, Padua, Italy

Cytobrushing is the most common technique used to sample the equine ocular surface. Impression cytology (IC) is an innovative, non-invasive method, which allows to collect the superficial layers of ocular epithelium. It's routinely used in human medicine while in veterinary medicine it has not been commonly applied yet. IC has been experimented first in dogs and cats [1,2], but few studies in large animals have been done [3]. The aims of this study are: 1) to compare cytobrush technique and impression cytology of the cornea and bulbar conjunctiva of healthy equine eyes; 2) to assess the agreement between two observers with different level of expertise; and 3) to evaluate the normal pattern of ocular impression cytology in the horse.

Twenty-four horses were sampled few minutes after slaughtering. All samples were obtained from superior limbus using IC on the left eye and cytobrush on the right eye. Specimens were stained with Wright-Giemsa stain and evaluated by two observers with different expertise, a board-certified clinical pathologist and a post-doc researcher with 3 years of experience in cytology. Cellularity, preservations of morphology, different cellular types' morphology, presence of goblet and inflammatory cells were evaluated using a four-grades scoring system.

In IC samples, corneal and conjunctival cells were clearly recognized and separated. IC samples showed good preservation and cellularity for both cell population in 16 out of 24 samples (66%) and 6/24 (25%), respectively. Good preservation and cellularity were limited to only one cell population in 8 samples (33%) and 7 (29%), respectively. In 6 IC samples (25%) inflammatory cells were noticed and in only 5 samples (24%) goblet cells were present. Cytobrush specimens appeared well preserved in 15/24 (63%) cases and with good cellularity in 7/24 (29%) for both cells types. Both corneal and conjunctival cells were present, but without a clear separation. Cellularity, preservation and the enumeration of goblet cells were higher in IC compared to brush technique ($P= 0.013$; $P=0.004$; $P=0.031$). There was moderate to fair agreement about cellular morphology in IC between observers.

IC of ocular surface in horses gives samples with good cellularity and well-preserved, better than cytobrush samples. Moreover, goblet cells were found easier with impression cytology. However, cytobrushing, that allows bigger magnification, is recommended to evaluate more specific details of cytoplasm and nucleus.

[1] Perazzi A, Bonsembiante F, Gelain ME, Patruno M, Di Iorio E, Migliorati A, Iacopetti I. Cytology of the healthy canine and feline ocular surface: comparison between cytobrush and impression technique. *Vet Clin Pathol.* 2017 Mar; 46(1):164-171. [2] Eordogh R, Schwendenwein I, Tichy A, Nell B. Impression cytology: a novel sampling technique for conjunctival cytology of the feline eye. *Vet Ophthalmol.* 2015;18:276–284. [3] Braus BK, Lehenauer B, Tichy A, Nell B, Schwendenwein I. Impression cytology as diagnostic tool in horses with and without ocular surface disease. *Equine Vet J.* 2016 Nov 12.

A DEGENERATIVE LEUKOMYELOENCEPHALOPATHY OF UNKNOWN ORIGIN IN AN AZAWAKH DOG

Maria Teresa Mandara (1), Greta Foiani (1), Federica Balducci (2), Marco Bernardini (2)(3)

(1) Università degli Studi di Perugia, Dipartimento di Medicina Veterinaria. (2) Ospedale Veterinario "I Portoni Rossi", Zola Predrosa (BO). (3) Università degli Studi di Padova, Dipartimento di Medicina, Produzione e Sanità Animale.

The term "leukodystrophy" is generally used to describe inherited and progressive disorders primarily and directly affecting the myelin of the Central Nervous System (CNS) [1]. In veterinary neuropathology leukodystrophies are more strictly considered as disorders of myelin synthesis and maintenance distinguished from insufficient or retarded production of myelin (hypomyelination), affecting bilaterally symmetrical selective areas of the white matter, with destruction of myelin and eventually axons [2]. Diseases displaying a comparable confluent primary progressive loss of myelin, but lacking a frank evidence of genetic origin are referred to as "leukoencephalopathies" [1]. A number of leukodystrophies and degenerative myelopathies have been described in selective canine breeds, not infrequently of difficult classification. In Azawakh dog, degenerative diseases have been reported neither in the CNS, nor in the Peripheral Nervous System.

The aim of this study is to describe neuropathological findings of a degenerative disorder primarily affecting the spinal cord in a 6-year-old male Azawakh dog showing a history of slowly progressive ataxic syndrome of seven months duration associated with sensory disorders.

Gross and histological examination by Luxol fast blue-PAS and Bielschowsky stains were performed on CNS. Additional IHC was performed on selected FFPE brain and spinal cord sections using avidin-biotin peroxidase complex staining for glial fibrillary acidic protein (GFAP, Dako, Carpinteria, California, USA) and neurofilaments (NF, Biomol, Plymouth Meeting, PA, USA). Additional semithin and ultrathin sections were also obtained from the cervical spinal cord and selected peripheral nerves.

A diffuse bilaterally symmetrical leukomyelopathy was observed consistent with severe bilaterally symmetrical demyelination and vacuolisation confined to the dorsal columns along all the spinal cord with a minor axonal degeneration. The main changes of myelin sheath consisted in splitting and intramyelin edema. Myelin sheath free axons were scattered in a network of astrocytic processes and isolated collagen fibres. Few reactive macrophages exhibiting a foamy pattern were observed adjacent to the small vessels. In the brain, a spongy change was observed in the raphe nuclei, spinal tract and nuclei of trigeminal nerve, and rostral cerebellar peduncles. Lesions were not found in peripheral nerves, nor in the spinal ganglia.

To our knowledge, this is the first neurodegenerative disease described in Azawakh dog. Considering the late age of onset and the lack of a similar neurological disorder in related dogs, an inherited origin remains doubtful. A nutritional or toxic-metabolic disorder cannot be excluded in the pathogenesis of the lesions.

[1] Powers J.M., De Vivo D., 2002. Peroxisomal and mitochondrial disorders. In: Greenfield's Neuropathology (7th Edit), Arnold, London. pp. 737-758. [2] Vandeveld M., Higgins R.J., Oevermann A., 2012. Veterinary Neuropathology – Essentials of Theory and Practice. Wiley-Blackwell (1st Edit), Ames, Iowa (USA), pp. 173-178.

UNRAVELLING A MYSTERY: CHARACTERIZATION OF INFLAMMATORY INFILTRATE OF ULCERATIVE DERMATITIS IN MICE

Davide De Biase (1), Francesco Esposito (2), Giuseppe Piegari (1), Valentina Iovane (1), Giuseppe Palma (3), Claudio Arra (3), Serenella Papparella (1), Alfredo Fusco (2) and Orlando Paciello (1)

(1) Dipartimento di Medicina Veterinaria e Produzioni Animali, Università Degli Studi di Napoli "Federico II" (2) Istituto per l'Endocrinologia ed Oncologia Sperimentale del CNR e/o Dipartimento di Medicina Molecolare e Biotecnologie Mediche, Università degli Studi di Napoli "Federico II" (3) SSD Sperimentazione Animale, Dipartimento di Oncologia Sperimentale, Istituto Nazionale per lo Studio e la Cura dei Tumori "Fondazione G. Pascale"

Ulcerative dermatitis (UD) is an idiopathic, spontaneous and progressive disease typically affecting aged mice on a C57BL/6 background [1]. This condition is clinically characterized by intense pruritus and scratching leading to severe skin lesions that are resilient to treatment [1]. Although several etiologic factors have been implicated in the development and progression of UD, the etiopathogenesis of this disease is still largely unknown [1]. Hence, we have evaluated the phenotypes of inflammatory infiltrate in UD skin lesions in order to provide some new insights on UD pathogenesis. For this study, we analyzed moderate to severe cases of ulcerative dermatitis observed in 20 out of 60 transgenic mice with a C57BL/6 background. Immediately after euthanasia, skin samples were fixed in 10% neutral buffered formalin for histopathology or cryopreserved for molecular analysis. 10 unaffected skin biopsies from mice with a C57BL/6 background were used as negative controls. Four- μ m paraffin sections were stained with haematoxylin and eosin (HE) and toluidine blue (TB). Moreover, immunohistochemical analysis for CD3, CD45, CD4, CD8, IL-17 and MHC II was performed to characterize and quantify lymphocytic infiltrate. Macroscopically, lesions varied from coalescing crusts to irregularly shaped areas of ulceration extending mostly to the dorsal cervical region. Histologically, affected skin revealed extensive areas of ulceration and a diffuse, severe and mixed inflammatory infiltrate in the dermis, often reaching deep underlying structures, consisting mostly of lymphocytes, neutrophils and macrophages. No relevant changes were observed in control's skin. We also observed an increase of mast cells in the affected skin compared to controls, a predominant CD3 and CD4 positive lymphocytes with a fewer number of CD45 positive cells and IL-17 positive lymphocytes and mast cells. No immunoreaction was observed for CD8 antibody. Moreover, a MHC class II immunoreaction of dermal and subcutaneous endothelial cells as well as inflammatory cells was also detected. Gene expression array of affected mice showed an upregulation of ST2 gene. ST2 gene have been demonstrated to play an essential role in allergic Th2 response [2], while little is known about the interaction between ST2 gene products and Th17 cells, but some authors recently suggested that also Th17 cells, together with Th2 cells, may be involved in the pathogenesis of allergic airway disease in mice [3]. Although the causative trigger of ulcerative dermatitis is still not completely understood, our preliminary data lead to further investigate the hypothesis that UD in mice have an allergic etiopathogenesis.

[1] Hampton et al. Progression of ulcerative dermatitis lesions in C57BL/6CrI mice and the development of a scoring system for dermatitis lesions, *Journal of the American Association for Laboratory Animal Science* 51.5:586-593, 2012. [2] Oshikawa et al. Expression and function of the ST2 gene in a murine model of allergic airway inflammation, *Clinical & Experimental Allergy* 32:1520-1526, 2002. [3] Vocca et al. IL-33/ST2 axis controls Th2/IL-31 and Th17 immune response in allergic airway diseases, *Immunobiology* 220:954-963, 2015.

ALOPECIA X, CYCLICAL FLANK ALOPECIA AND FOLLICULAR DYSPLASIA: EXPRESSION OF P63 IN CANINE HAIR FOLLICLE

Sabrina Vanessa Patrizia Defourny (1), Ramona Di Matteo (1), Mariarita Romanucci (1), Filippo De Bellis (2), Antonella Vercelli (3), Marcella Massimini (4), Leonardo Della Salda (1)

(1) Università degli Studi di Teramo, Facoltà di Medicina Veterinaria, Italy. (2) London Vet Specialists, 56 Belsize Lane, London. (3) Ambulatorio Veterinario Associato, Torino, Italy. (4) Istituto Zooprofilattico Sperimentale Abruzzo e Molise.

Skin diseases characterized by alopecia are generally associated with a deregulation of the Hair Cycle (HC) or an abnormal development of the Hair Follicle (HF), although their pathogenesis is not completely defined. Adult skin contains several reservoirs of stem cells (SCs) located in the epidermis, HFs and probably sebaceous glands. P63, a member of the p53 family of proto-oncogenes, is a transcription factor that is likely to play a key role in regulating self-renewal and long-term proliferative capacity of SCs [1]. P63 is also important in skin development and homeostasis, by promoting cell proliferation in basal and suprabasal epidermal cells, as well as in the outer root sheath (ORS) and matrix of HFs [2]. The immunohistochemical evaluation of p63 expression in the scalp of affected (frontal) and unaffected (occipital) skin of human patients with androgenetic alopecia showed that the root sheaths from occipital skin had significantly higher expression of p63 in comparison to frontal areas [3]. The aim of our study was to evaluate the immunohistochemical expression of p63 in 15 necropsy samples of canine normal skin and 16 skin biopsy samples from dogs affected by Alopecia X (n=10), Cyclical flank alopecia (n=4) and Canine follicular dysplasia (n=2), in order to determine if this molecule may be involved in the pathological mechanisms of HC arrest and if there are differences in p63 expression between the various types of canine alopecia. The number of p63-positive nuclei in HF cells for each sample was calculated in 10 randomly selected high-power (×400) fields, counting at least 1000 positive nuclei, and expressed as a percentage. P63 expression was only detectable in the ORS cells and bulbs of HFs, with a significantly higher nuclear score in canine normal skin (89.9%; +/- 2%) when compared to affected skin (76.3%; +/- 4,7) ($p < 0.001$). On the other hand, HF papilla and inner root sheath (IRS) were negative for p63 in both normal and pathological samples. Although p63 immunoexpression appeared to be higher in Alopecia X (77.2%) when compared to the other pathological groups, especially Canine follicular dysplasia (71%), differences did not reach statistical significance due to the limited number of samples available for dysplastic diseases. In addition, a higher variability of expression was detected between the different pathological samples in comparison to normal samples. These findings indicate a partial loss of p63 expression in canine HF diseases, similarly to the changes observed in human androgenetic alopecia [2]. On the basis of these results, p63 may be supposed to play a role in the pathogenesis of impaired follicular regeneration and HC arrest occurring in the investigated canine HF diseases.

[1] Laurikkala et al. p63 regulates multiple signalling pathways required for ectodermal organogenesis and differentiation. *Development* 133: 1553-1563, 2006. [2] Zheng et al. Ginsenosides Rb1 and Rd Regulate Proliferation of Mature Keratinocytes Through Induction of p63 Expression in Hair Follicles. *Phytother. Res* 27: 1095-1101, 2013. [3] Fiuraskova et al. Expression of beta-catenin, p63 and CD34 in hair follicles during the course of androgenetic alopecia. *Arch. Dermatol. Res* 297: 143-146, 2005.

EXPRESSION AND BIOCHEMICAL PROPERTIES OF CELLULAR PRION PROTEIN IN SKELETAL MUSCLE OF COWS ARE NOT AGE DEPENDENT

Teresa Bruna Pagano (1), Fabienne Serra (2), Davide De Biase (1), Torsten Seuberlich (2), Anna Oevermann (2), Serenella Papparella (1) and Orlando Paciello (1)

(1) Università degli Studi Federico II di Napoli, Dipartimento di Medicina Veterinaria e Produzioni Animali, Italy

(2) University of Bern, Vetsuisse Faculty, NeuroCenter, Division of Neurological sciences, Switzerland

The cellular prion protein (PrP^C) is a membrane-bound sialoglycoprotein highly expressed in the nervous tissue while present at a lower level in skeletal muscle and other organs. PrP^C is essential for prion propagation in human and animal prion diseases, characterized by accumulation of an aberrant, proteinase resistant, isoform of PrP (called PrP^{Sc}) predominantly in the brain. PrP^C overexpression has been described in many different human neuromuscular disorders (1). Little is known about the expression of PrP^C in health and disease in bovine's muscle tissue. The aim of this study was to evaluate the presence, the molecular and biochemical properties of PrP^C in skeletal muscle of cows as well as their possible changes in muscle aging. Skeletal muscle and brain samples of 12 aged (7-22 years old) and 8 young (1 year old) cross-breed Podolica cows were collected at the slaughterhouse and snap frozen in liquid nitrogen. All the brains were tested BSE negative. Muscle cryosections were examined by a standard panel of histological and histoenzymatic stains as well as immunohistochemistry for PrP and desmin. Immunoblot was performed on muscle and brain homogenates in order to analyze the amount of PrP^C, its glycosylation profile, proteinase resistance, solubility levels after high speed centrifugation and tendency to aggregate by sucrose gradient assay (2). Histologically, muscle biopsies of aged cows showed myopathic features such as vacuolated fibers (67%), angular atrophy (58%), degenerated fibers (66%) and lymphocytic inflammation (40%) as already described in bovine sarcopenia (3). Vacuolated muscle fibers, degenerated fibers and less severe angular atrophy were found in a lower number of young animals (25 and 12%, respectively). Immunohistochemistry for PrP revealed a distinct granular positivity in intramuscular nerve branches and muscle spindles in all cases. A faint membrane positivity was evident in about 50% of cases, occasionally associated with angular and atrophic fibers. A focal subsarcolemmal granular positivity was found in degenerated fibers (desmin depleted) of both young (30%) and old (66%) animals with an increased immunolabeling of rimmed vacuoles. Occasionally, mononuclear endomysial infiltrate was PrP positive as well. No differences between muscles and brains of young and old animals were detected by quantitative immunoblot and Proteinase K titration. The glycoform profile and the molecular mass of PrP^C in muscle samples appeared slightly different compared to the brain. Sucrose gradient velocity sedimentation gave variable results, with a generally lower amount of PrP in high density sucrose fractions in the muscle compared to the brain. After high speed centrifugation the majority of muscle PrP^C was found in the soluble fraction, without significant differences between young and old animals. Our preliminary data suggest that: 1) PrP^C is overexpressed in degenerated, vacuolated and atrophic muscle fibers; 2) The glycoform profile of PrP^C differs between brain and muscle tissue; 3) Detergent solubility, PK resistance and PrP^C aggregation in skeletal muscle do not increase with age.

1- Kovács GG, et al. The prion protein in human neuromuscular diseases. *J Pathol.* 2004. 2- Serra F, et al. PrP-C1 fragment in cattle brains reveals features of the transmissible spongiform encephalopathy associated PrP^{Sc}. *Brain Res.* 2017. 3- Costagliola A, et al. Age related changes of skeletal muscle of cattle. *Vet Pat.* 2016.